



Case of the Quarter: Q2 2016

Alexey Hodkoff, MD and Don Xu, MD, PhD

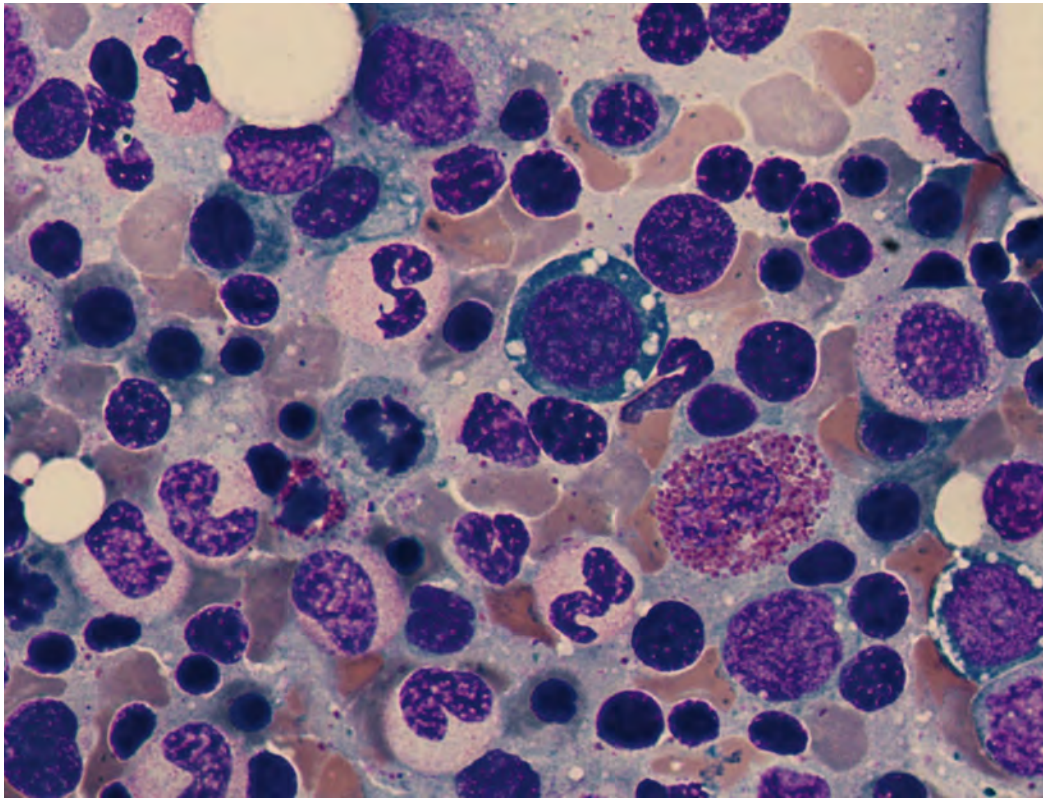
I: Clinical History

A 65-year-old male was referred to oncology clinic for evaluation of thrombocytopenia and mild macrocytic anemia for several of years. Other past medical history included morbid obesity (s/p bariatric surgery), type 2 diabetes mellitus, peripheral neuropathy, hypertension, hyperlipidemia, and worsening tremors and unsteadiness over several years.

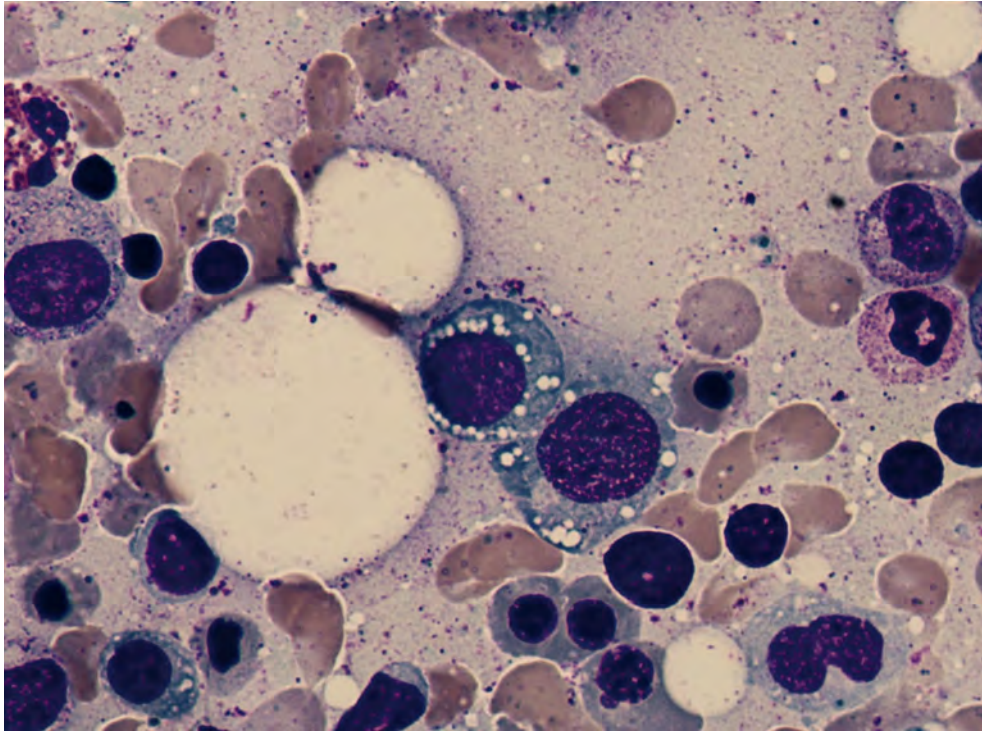
CBC indices were: WBC 5.0 K/uL; RBC 3.10 M/uL; Hgb 11.9 g/dL; Hct 32.2%; MCV 103.9 fL; Plt 75 K/ul. Automated differentials were: neutrophils 68.8%; lymphocytes 20.1%; monocytes 10.3%; eosinophils 0.2%; and basophils 0.2%.

His vitamin B12 and folic acid levels were normal. A bone marrow biopsy was performed to rule out MDS.

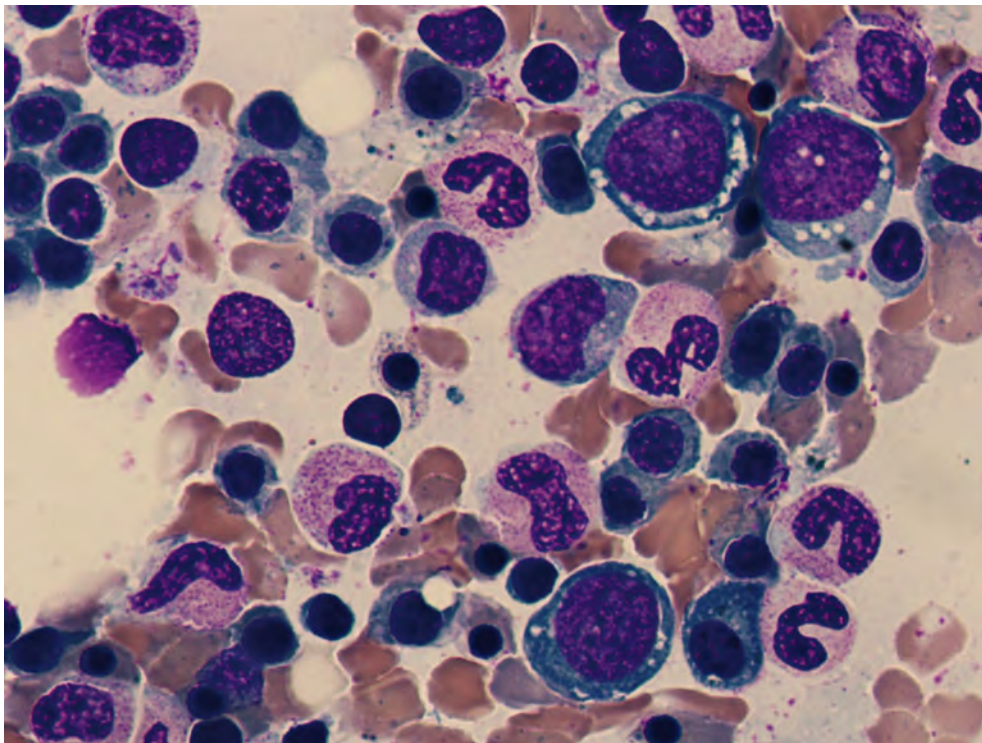
II: Microscopic Findings:



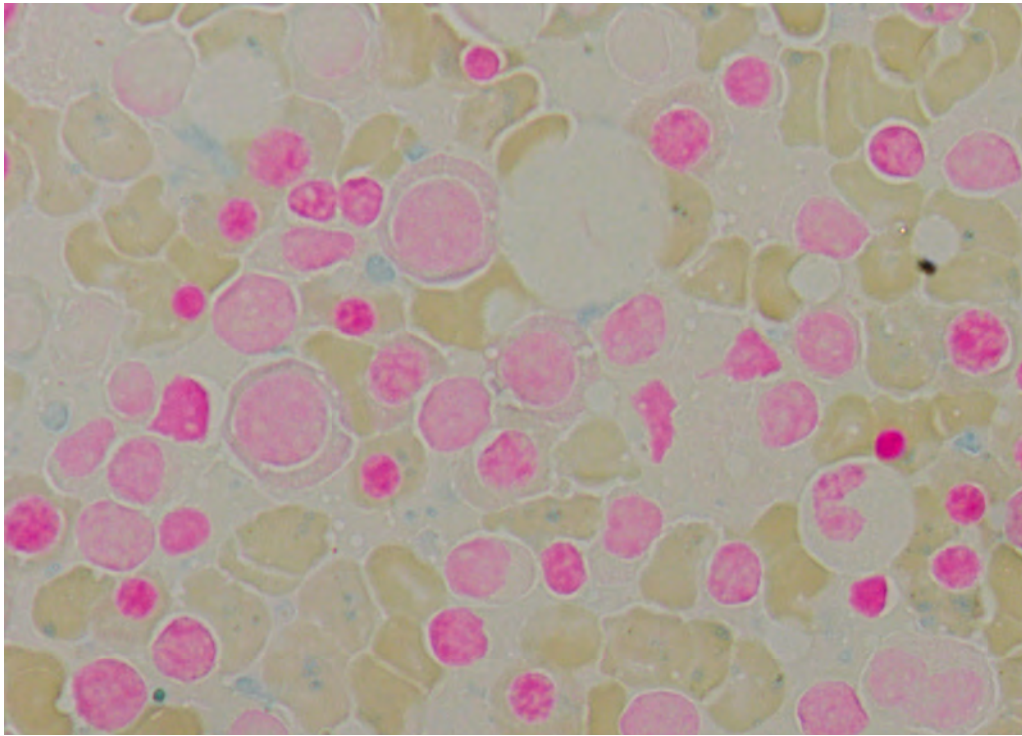
Bone marrow aspirate, Wright-Giemsa stain, 1000x



Bone marrow aspirate, Wright-Giemsa stain, 1000x



Bone marrow aspirate, Wright-Giemsa stain, 1000x



Bone marrow aspirate, iron stain, 1000x